

Notching in the Posterior Border of the Ramus of Mandible in a Patient with Neurofibromatosis Type I – A Case Report

BHUVANA KRISHNAMOORTHY¹, PARUL SINGH², SUMA GUNDAREDDY N³, MANISHA LAKHANPAL SHARMA⁴, MANU DHILLON⁵

ABSTRACT

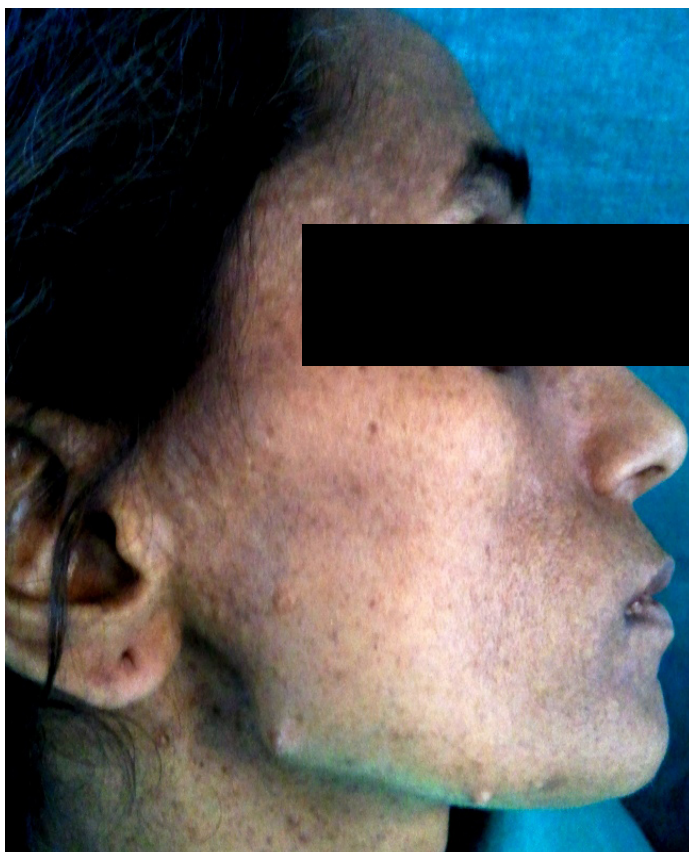Neurofibromatosis Type I (NFI) is a relatively common hereditary, autosomal dominant neurocutaneous condition. It is a benign peripheral nerve sheath tumour arising from Schwann cells and peripheral fibroblasts. Even though it is a neurocutaneous disorder, NF I has significant skeletal manifestations. Oral and maxillofacial skeletal structures are also often involved in the form of deepening of sigmoid notch, enlarged mandibular canal and notching of inferior border of mandible. In this paper, we are reporting a female patient of NF I who presented with a notching in the posterior border of ascending ramus of mandible.

Key words: Neurofibromatosis Type I, Mandible, Neurofibromin

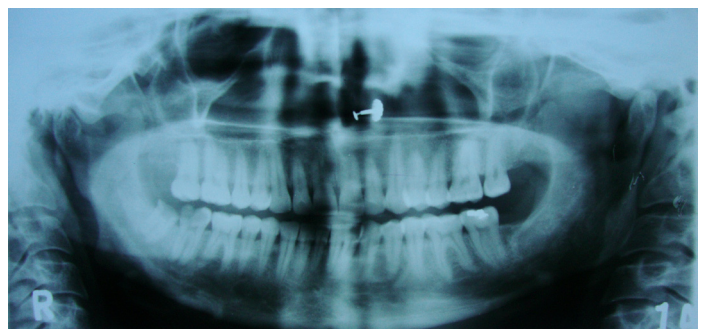
CASE REPORT

A 38-year-old, Indo-Asian female reported to Department of Oral medicine and Radiology with chief complaint of pain in right mandibular posterior tooth. She gave no history of trauma or surgery. The patient was of short stature and had multiple skin nodules that were asymptomatic. Café a lait spots, measuring more than 7 cm, were present at multiple sites on the body. Patient's mother and sister had similar findings. On extra-oral examination, patient revealed gross facial asymmetry due to a well defined concave

defect in the right side. Also, due to this deformity, the right gonial angle was more acute as compared to the left one [Table/Fig-1]. The panoramic radiograph revealed deepening of the left coronoid notch, enlargement of bilateral mandibular canal and increased branching of the mandibular canal. A well-defined notching was present on the right posterior border of the ascending ramus [Table/Fig-2]. A clinical diagnosis of Neurofibromatosis Type I was given, based on clinical criteria of the National Institutes of Health Consensus Development Conference [1]. Since she met more than two of the minimum required criteria according to the consensus, no additional investigations were carried out.



[Table/Fig-1]: A well-defined notching is present on the posterior ascending ramus of the mandible on the right side. Also evident on the skin of the face are numerous well defined nodules



[Table/Fig-2]: Panoramic radiograph showing the distinct notching on the posterior ascending ramus of the mandible on the right side. Accentuated coronoid notch on the left side and enlargement of mandibular canal on both sides can also be appreciated

DISCUSSION

NFI is a pleiotropic multisystem hamartomatous disorder with no sex predilection. It is caused by a mutation of the gene responsible for the production of neurofibromin, a tumour suppressor protein [1]. Individuals with NFI are at risk for skeletal abnormalities. Recent research indicated that NFI osteoprogenitor cells demonstrate increased osteoclast forming capacity, increased migration, adhesion, and in vitro bone resorption and hence, they may contribute to skeletal defects [2]. However, notching of the posterior border of the ramus of mandible, which was seen in our patient, has not been reported in literature till date. Also, recent reports suggest that most patients have tumours which are contiguous to the altered bone and hence, caution must be exercised whenever there is a bone dysplasia in a patient with NFI.

CONCLUSION

Osseous involvement in NFI is characteristic, but it differs among patients and the mandible is often affected. Knowledge on such skeletal changes is essential, since oral diagnosticians should always suspect a neoplasm which is contiguous with a bone deformity in a patient with NFI.

REFERENCES

- [1] Georgescu EF, Stanescu L, Georgescu AC, Dumitrescu D, Foarfa C, Calin G. Bone abnormalities occurring in the follow-up of the patients with neurofibromatosis type 1. *Roman J Morphol Embryol*. 2007;48(3):249-56.
- [2] Stevenson DA, Yan J, He Y, Li H, Liu Y, Zhang Q, Jing Y, et al. Multiple increased osteoclast functions in individuals with neurofibromatosis Type 1. *Am J Med Genet A*. 2011; 155(5): 1050-59.

PARTICULARS OF CONTRIBUTORS:

1. Associate Professor, Department of Oral Medicine and Radiology, ITS- Centre for Dental Studies and Research, Muradnagar, Ghaziabad, UP, India.
2. Post Graduate Student, Department of Oral Medicine and Radiology, ITS- Centre for Dental Studies and Research, Muradnagar, Ghaziabad, UP, India.
3. Professor and Head, Department of Oral Medicine and Radiology, ITS- Centre for Dental Studies and Research, Muradnagar, Ghaziabad, UP, India.
4. Reader, Department of Oral Medicine and Radiology, ITS- Centre for Dental Studies and Research, Muradnagar, Ghaziabad, UP, India.
5. Senior Lecturer, Department of Oral Medicine and Radiology, ITS- Centre for Dental Studies and Research, Muradnagar, Ghaziabad, UP, India.

NAME, ADDRESS, E-MAIL ID OF THE CORRESPONDING AUTHOR:

Dr. Bhuvana Krishnamoorthy,
Associate Professor, Department of Oral Medicine and Radiology, ITS- Centre for Dental Studies and Research,
Muradnagar, Ghaziabad- 201206, UP, India.
Phone: 9999509465, (01232) 225380, E-mail: bhuvanakrishnamoorthy@yahoo.com

FINANCIAL OR OTHER COMPETING INTERESTS: None.

Date of Submission: **Feb 25, 2013**
Date of Peer Review: **Jul 14, 2013**
Date of Acceptance: **Aug 04, 2013**
Date of Publishing: **Oct 05, 2013**